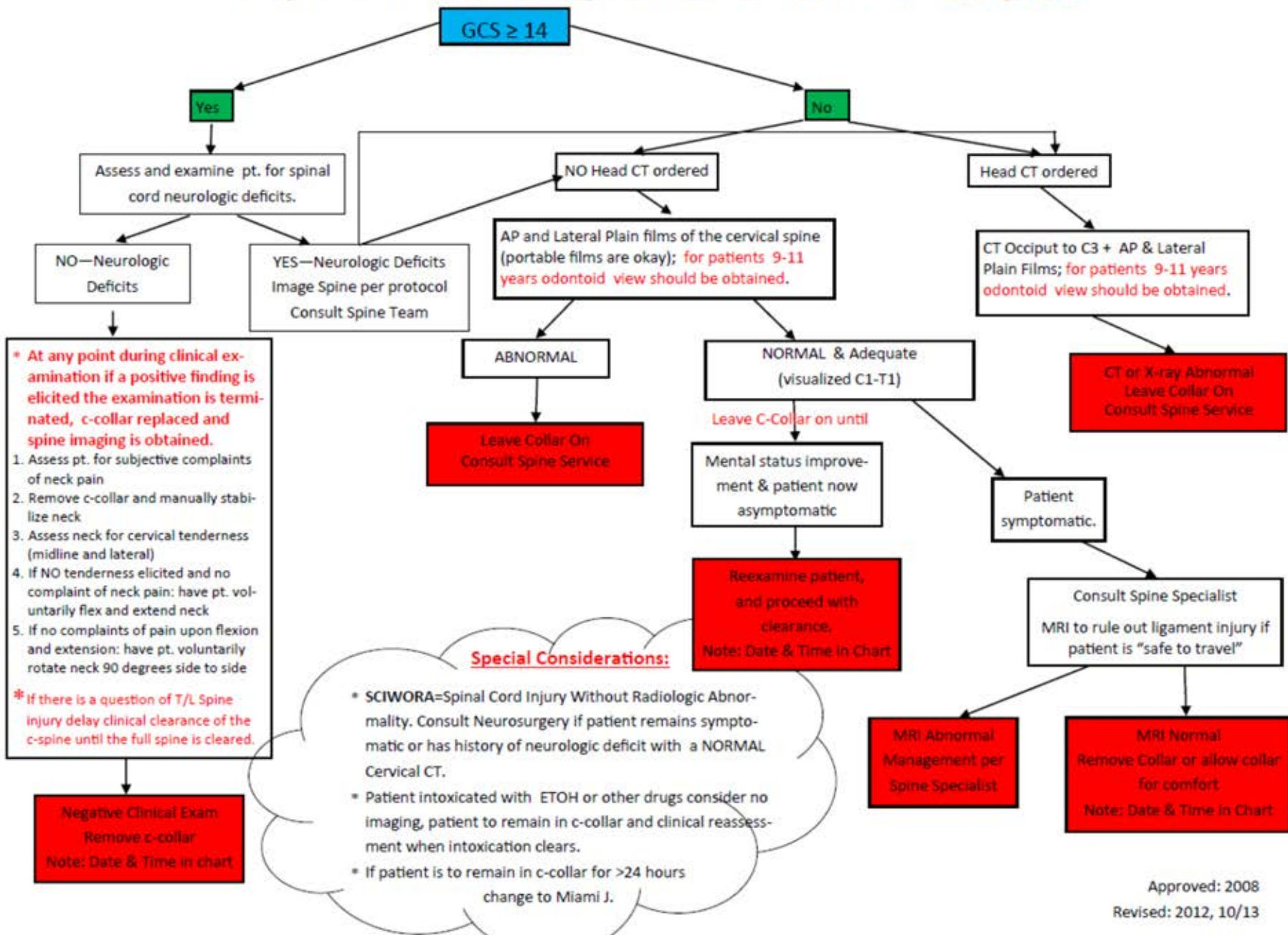


C-Spine Clearance Algorithm for those 0–10 years



*** At any point during clinical examination if a positive finding is elicited the examination is terminated, c-collar replaced and spine imaging is obtained.**

1. Assess pt. for subjective complaints of neck pain
2. Remove c-collar and manually stabilize neck
3. Assess neck for cervical tenderness (midline and lateral)
4. If NO tenderness elicited and no complaint of neck pain: have pt. voluntarily flex and extend neck
5. If no complaints of pain upon flexion and extension: have pt. voluntarily rotate neck 90 degrees side to side

*** If there is a question of T/L Spine injury delay clinical clearance of the c-spine until the full spine is cleared.**

Special Considerations:

- **SCIWORA**=Spinal Cord Injury Without Radiologic Abnormality. Consult Neurosurgery if patient remains symptomatic or has history of neurologic deficit with a NORMAL Cervical CT.
- Patient intoxicated with ETOH or other drugs consider no imaging, patient to remain in c-collar and clinical reassessment when intoxication clears.
- If patient is to remain in c-collar for >24 hours change to Miami J.